

The Implications of Hyperglycemia in Maxilo-Facial Surgery

OANA ELENA CIURCANU¹, VASILICA CRISTESCU^{2*}, RALUCA DRAGOMIR³, VLAD DANILA¹

¹Grigore T. Popa University of Medicine and Pharmacy Iasi, Faculty of Dental Medicine, Discipline of Dento-Alveolar Surgery, Anesthesiology and Medical-Surgical Emergencies, 16 Universitatii Str., 700115, Iasi, Romania

²National Institute of Diabete, Nutrition and Metabolic Disease N.C Paulescu, 5-7 Ion Movila Str., 030167, Bucharest, Romania

³Grigore T. Popa University of Medicine and Pharmacy, Faculty of Dental Medicine, Department of Anesthesiology and Oral Surgery, 16 Universitatii Str., 700115, Iasi, Romania

In surgical practice, the problems raised by diabetics are extremely complex and require for solving the knowledge of both the physiopathological disorders characteristic of these disease and the changes caused on this pathological field by various dental aggressions. Sometimes, patients with complications of undiagnosed diabetes mellitus are present in the dentistry where all problems of dental and metabolic therapeutics must be solved by the dentist. The lack of knowledge of the general pathophysiology data of the diabetic mellitus disease and of the metabolical rebalancing methods of these patients on dental aggressions as well as the lack of early knowledge of the events that precede the installation of real metabolic dramas can lead to disaster. The diabetic patient may present in time various dental conditions, some of which are directly or indirectly related to diabetic disease - lesions in the oral cavity are polymorphic and physiologically interpreted in a very different way. The oro-dental changes in diabetes mellitus have as substrate the degenerative arterial involvement in the context of early tissue aging. The hypoglycemia is a factor that makes doctors reluctant to maintain normal blood sugar levels in diabetic anesthetized patients. Hyperglycemia leads to glucosuria, then polyuria, which in turn causes dehydration of the patient through osmotic diuresis. Hyperglycemia decreases the patient's ability to resist infections. During a period of 6 years, 2011-2016, we observed, treated and monitored a number of 75 patients with diabetes mellitus. Of these, 45 were men and 30 women and the age was between 18-65 years, with the highest incidence between 45-60 years. The importance of diabetic mellitus field in dental practice is not only determined by the high frequency of complications requiring surgery, but also that in these patients any aggression, even limited, can cause entry into a vicious circle where the local lesion aggravates the diabetic state and in turn it worsens the local development of the lesions. The appropriate premedication, protective antibiotic therapy, quality loco-regional anesthesia, rigorous applying of aseptic and antiseptic rules, soft, non-traumatic maneuvers, are mandatory measures addressed to the diabetic patient for performing risk-free surgery.

Keywords: pathophysiological disorders, hypoglycemia, glucose, dehydration

Diagnosis is not an purpose in itself; it always has an end, aiming at *establishing therapeutic demeanor and estimating prognosis*, two essential elements of medical practice.

For this, the physician from all the specialties has three successive stages: anamnesis, general physical examination and biological paraclinical exams. We have to take into account the possibility of congenital abnormalities also [1]. In this sense, the tolerant and careful dialogue, duly conducted and adopted by the individual personality, allows the physician to highlight individual characteristics of each patient [2].

The essential characteristic of diabetes mellitus is chronic hyperglycemia, but it is necessary to underline that it is not about *a jeun* hyperglycemia, which occurs relatively late in disease progression, especially in non-insulin-dependent diabetes mellitus.

Hyperglycemia is due to an absolute or relative lack of insulin, which is synthesized, stored and secreted by beta pancreatic cells. Insulin is the only hypoglycemic hormone and has an important anabolic action on lipid and protein metabolism, favoring lipogenesis and protein synthesis.

Diabetes mellitus clinical picture is characteristic only in advanced forms when polyuria, polydipsia, polyphagia and weight loss may occur. In early stages symptoms are lacking.

The physical examination does not reveal any changes

except in the advanced stage of metabolic imbalance, respectively in the pre-coma and diabetic coma or when other complications have occurred. Laboratory specimens are of a very particular utility, giving certainty for the diagnosis of the disease.

Complications (acute and chronic) darkens to an important extent the prognosis of the disease as it can cause severe disability or death. They will decrease in frequency and severity if diabetes mellitus is detected early and treated appropriately.

In surgical practice, the high problems of diabetics are extremely complex and require for their solving the knowledge of both the pathophysiological disorders characteristic of diabetic disease and the changes caused on this pathological field by various dental aggressions.

The lack of knowledge of the general pathophysiology data of the diabetic mellitus disease and of the metabolical rebalancing methods of these patients on dental aggressions as well as the lack of early knowledge of the events that precede the installation of real metabolic dramas can lead to disaster.

Diabetic patient may present various dental conditions during life, some of which are directly or indirectly related to diabetic disease. The lesions in the oral cavity are polymorphic and physiologically interpreted very differently.

Oral-dental changes in diabetes mellitus have as a

* email: lali.cristescu@yahoo.com; dragomir.raluca@umfiasi.ro

substrate the degenerative arterial involvement, due to early tissue aging.

There are no pulp changes in the undamaged teeth; in the dental caries, the pulp presents acute inflammatory tendencies or frequent pulpal abscesses and retrograde pulp necrosis. Cement show modifications of its structure, with fine liming salts being observed. As regards saliva, diabetics have a decrease in salivary flow, explained by diabetic polyuria or through the salivary gland hypofunction, following a diffuse process of glandular sclerosis.

Saliva flow dynamics produces some localized lesions at the mouth: cracked lips with bleeding crusts, dry, lacquer jaw mucos, red, fissured, tongue. Persistent dryness of the mouth causes a hale with a slight smell of raw apple. In saliva, glucose concentration is slightly increased, microbial virulence is conditioned by decreased salivary secretion. Salivary litiasis is frequently found in diabetics. Dental plaque are common [3].

Parotid hypertrophy often occurs in diabetes and sometimes it is painful. The pathogenic mechanism of diabetic parotidosis is dismetabolic with lipid storage in parotid glands also.

Diabetic gingivitis concerns only the covering periodontium, without the alveolar ligaments and the alveolar bone.

Chronic superficial periodontitis is very common in younger age, considered as an early manifestation of the disease.

The patient complains of gingival pruritus and has gingival bleedings, fetid hale, gingival hyperaemia, premature bone demineralization.

When chronic deep marginal periodontitis occurs the patient is embarrassed by mastication, tooth mobility, fetid hale, purple appearance of gums due to stasis, purulent secretion, dental mobility. Periodontopathies in diabetes mellitus occur in a proportion of 60-95%. They begin early, evolve rapidly, lead to partial or total edentations even in young people.

Hyperglycemia is the expression of the decrease in intracellular glycolysis and it results in periodontal damage due to the reduction or inactivity of insulin. Any level of hyperglycemia is responsible for the tendency to chronic infections in periodontitis.

Diabetic stomatitis is characterized by dry mouth, gingival pruritus, buccal pyrexia, gingivoragia, pruritus at anterior 1/3 of the tongue, acetone odor.

The oral mucosa is red with ulcerated gingival edges, increased and slightly bleeding interdental papillae, dental mobility.

Ultero-necrotic stomatitis can aggravate the disease but diabetes mellitus can also cause ultero-necrotic stomatitis. Cheilitis are another manifestation found in diabetics. They are characterized by dry lips, covered with seromas, ragged comisurality. There is also an increased frequency of glosses in the sense that the tongue is enlarged by volume, grooved, hyperemiate fuziformes papillae. In other cases, the tongue is flaccid, atonic, with pain, tingling, pricking.

Post-surgical alveolitis are usually dry with poor healing, with a total lack of alveolar inflammation, pale gum, aton. Frequently, hemorrhages are presented by increasing the permeability and vascular fragility. Due to arterial walls and vasomotor disorders is not uncommon to install retrograde pulp necrosis.

There is no anesthesia technique that is *best* for the diabetic mellitus patient [4]. Each anesthesia must be a complex of substances, techniques and monitoring adapted to the physiological conditions of each patient and planned anatomical intervention. Modern inhalation

anesthesia is much used and modifies metabolism of carbohydrates; it causes a decrease in insulin secretion as a secondary effect of increasing sympathetic activity of norepinephrine.

Medico-legal objections were raised against loco-regional anesthesia in diabetics [5]. Many, perhaps all diabetics, suffer in some degree of diabetic neuropathy. Regional anesthesia is contraindicated because if the patient has a neurological postoperative deficit, the patient may then assign it to regional anesthesia. However, there is no evidence in the medical literature that regional anesthesia would aggravate a diabetic neuropathy. Regional anesthesia is associated with lower hyperglycemia than with non-diabetic patient anesthesia.

The final choice of anesthesia technique should only be made after careful consideration of the preoperative condition of the patient [6].

The anesthetist is in an unique position to intervene positively in caring for a diabetic patient who undergoes surgery. By monitoring blood glucose during surgery, besides other physiological variables and by using insulin to limit hyperglycemia, surgical experience may become more metabolically stable for the patient [7].

Experimental part

Materials and methods

In the Oral and Maxillofacial Surgery Clinic, during a 6-year period, 2011-2016 we, observed, treated and monitored a number of 75 patients with diabetes mellitus. Of these, 45 were men and 30 women and the age was between 18-65 years, with the highest incidence between 45-60 years.

Results and discussions

The interventions we performed in the 75 patients were in order of their frequency as follows: alveoloplastic extractions, incisions, evacuation and drainage of perimaxial abscesses, apical resection and suture of facial strips (fig. 1 and 2).

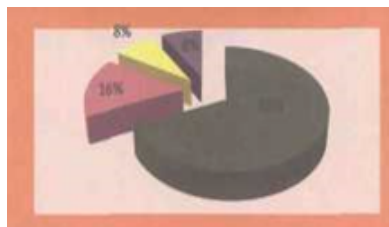


Fig. 1. Percentage of interventions of oral surgery and maxillofacial surgery - 68% extractions, 16% wound grooming, 8% apical resections and 8% incisions and evacuations

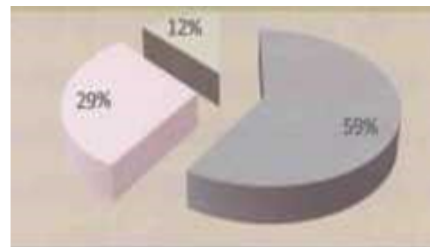


Fig.2. Indications for dental extraction - 59% deep marginal chronic periodontitis, 12% acute apical periodontitis, 12% radicular remains

The technique of oral surgery most commonly used by us in diabetic patients was dental extraction. This was especially indicated for teeth with deep chronic periodontitis, followed by stage I and II acute apical periodontitis in non-recoverable teeth and much less frequently for root debris.

The distribution of tooth extractions was performed: 6 patients one tooth, 18 patients 2 teeth; 15 patients 3 teeth, 6 patients 4 teeth, 6 patients 6 teeth.

Every diabetic who undergoes surgery regardless of its magnitude and duration, requires careful preparation for a better metabolic rebalancing that seeks to save him from

fearful postoperative complications [8].

Because these complications, especially the metabolic ones, are primarily the consequences of postoperative endocrine-vegetative reactions [9], the intensity of which is not always proportional to the severity of the aggression, we considered obligatory the postoperative preparation of the diabetics.

In all of our patients we took into account the stress created only in the thought of dental extraction and we have usually given premedication benzodiazepine, one mg per tablet, one hour before the surgical treatment [10].

We preferred the benzodiazepine derivatives because they have a pronounced anxiolytic, sedative and miorelaxant effect, extremely beneficial for diabetic patients and it is well-known that neurovegetative reactions underlie endocrine imbalances.

Diabetics also have a feature that we have in mind whenever we perform surgery: the imminent danger of infectious complications that threaten the diabetic patient during the postoperative period which imposed us a general demeanor, strictly adhered to all the patients solved surgically by us [11].

All surgical interventions (single and multiple extractions, incisions and evacuations of perimaxial abscesses, special resections and suture of facial lesions) were performed under antibiotic protection, oral antibiotic therapy, rigorously, accurately, started on the morning of the day of surgery [12].

The type of antibiotic, the dose and the interval of administration, we chose according to the severity of diabetes mellitus, in collaboration with the diabetologist [13].

Considering that anesthesia and the onset of intervention lead to increased glycogenolysis and glucose on the one hand and cortico-adrenal secretion on the other hand, we performed oral surgery only under loco-regional anesthesia with 1-2% xylene without adrenaline.

For clinical specificity, for ease of follow-up, and especially for individualization of proper preparation before and after extraction, we grouped the 75 patients with diabetes mellitus into four categories as follows: adult patients with non-vascular complications with diabetes mellitus, patients balanced by diet and oral medication - 30 cases - 40.00%, adult patients with diabetes mellitus with vascular lesions [14], balanced with diet and oral medication - 30 cases - 40.00%, patients with insulin-dependent diabetes mellitus - 9 cases - 12.00%; young diabetic patients with multiple coma, precoma, infections and piogene complications in the past - 6 cases - 8.00%.

We performed the following surgical interventions: at 30 patients - 40% apical resection, at 6 patients - 8.00%, incision, evacuation and drainage of a vestibular abscess, suture of a facial lesion and alveoplastic extractions in 18 patients - 24.00%. The extractions were as follows: 3 patients - 4.00% required a dental extraction, 9 patients - 12.00%, 2 dental extractions and 3 patients - 4%, 6 dental extractions.

In the morning of the intervention, patients started the antibiotic protection by administering 2 capsules (0.500g) of ampicillin, continued for 3 days postoperatively at 6 hours. The patient has not interrupted his usual work but has returned to control the first three days to observe local progression.

Adult patients with diabetes mellitus exhibit vascular lesions through coronary and cerebral atheromatosis balanced with diet and oral antidiabetic medication.

In 30 patients in this category we performed 2 incisions, evacuations and drainage of the perimaxillary abscesses, 4 sutures of four facial strips as well as dental extractions

in 21 patients. Dental extractions were 3 performed to 3 patients, 6 extractions to 6 patients, 4 extractions to 4 patients, 9 dental extractions to 9 patients and 6 extractions to 3 patients. On the morning of the intervention, we suppressed the treatment of the patient with anticoagulants and checked at the first hour that the prothrombin time was in no way under 40%.

We started antibiotherapy with semisynthetic penicillin (ampicillin, oxacillin), 2 capsules (0.500g), 3 days postoperatively, 2 capsules at 6 hour intervals.

We performed surgery quietly, without agitation, without brutality, with the dental armchair inclined to the horizontal. The patient continued his normal activity, but we insisted on the rigor of taking antidiabetic medication, the continuation of antibiotic therapy 3 days postoperatively, and especially resumption of anticoagulation therapy starting 24 hours postoperatively [15].

We solved 9 insulin dependent patients by incision, evacuation and drainage of a perimaxial abscess, and the other 6 dental extractions.

We had young diabetic patients with multiple coma and previous history of piogene complications. From this category we solved 6 patients in which we performed 3 dental extractions.

In these patients, care for the prevention of postoperative complications was greater, more careful, more cautious than other patients, and the protection of antibiotics was done parenterally.

The diabetic patient responds to surgical aggression through a favorable endocrine-vegetative reaction, but because of degenerative lesions present in various organs and because of metabolic instability, the effects of this reaction are not only less effective but also extremely dangerous.

Vascular atherosclerotic lesions diminish the efficiency of blood redistribution processes and by their presence on coronary and cerebral vessels, diabetics can hardly tolerate tension variations caused by anesthesia or surgery, sometimes causing serious postoperative complications (myocardial infarction, cerebrovascular accidents, etc.).

Hepatic, renal, and cerebral parenchymal lesions decrease the functional capacity of these organs. In addition, many diabetics are also obese, which makes the risks associated with diabetes overweight and obesity.

Of the most serious dangers that threaten the operated diabetic are determined by metabolic disorders related to the endocrine-vegetative reaction, which may result in the occurrence of two complications: hypoglycemia and acidosis [16].

Any diabetic who has been subjected to even minimal surgery - for example, dental extraction, incision and drainage of a perimaxillary abscess, etc., required a careful preparation that sought to ensure that by a correct metabolic rebalancing it sheltered from postoperative complications.

Because these complications and especially the metabolic consequences are primarily the consequence of the postoperative endocrine-vegetative reactions, the intensity of which is not always proportional to the severity of the aggression, the preoperative preparation of the diabetics is mandatory regardless of the extent of the intervention we undertake.

Preoperative treatment very useful for a compensated diabetic is absolutely mandatory for those with decompensated diabetes or with acidocetosis.

Today it is well-known that a well-balanced metabolic diabetic is not more exposed to complications than a non-diabetic.

Statistics show that with modern treatments the life of

diabetics has increased in all countries, as a result at least one in two diabetics arrives in a dental practice during their lives.

But the importance of diabetic mellitus impairment in practice is not only due to the high frequency of complications requiring surgery but also to the fact that in these patients any aggression, even limited, can cause entry into a vicious circle where the local lesion aggravates the diabetic state, and this, in turn, worsens the local development of lesions.

The decrease in defense capacity against infections and all post-aggressive reactivity coupled to decreased glycogen stores provide particularly fragile patients with a very low functional capacity, very sensitive to anesthetic and surgical trauma and able to report minor accidents, decompensations, reaching acid-ketosis, hyperosmolar or hypoglycemic coma.

Diabetic patients are highly responsive to the direct complications of anesthesia (hypoxia, hypotension, tensional oscillations, transient hypoglycemia).

Classical authors considered diabetics to be a land of high susceptibility to infections. New research has however made clear that well-balanced metabolic diabetes is not more exposed to infectious complications than non-diabetic.

The diabetic is often incapable of locating the infection at the entrance of the germ in the body due to the decrease in the effectiveness of cellular and humoral anti-infection defense mechanisms.

In a diabetic, an uncured vestibular abscess on time, fuses rapidly into the intermediate conjunctive spaces; a plague complicates in a few hours with lymphangitis and adenitis, and sometimes diabetics make septicophytomas from infective focal areas of minor importance (periodontal abscess, acute periapical osteitis, etc.); an insufficiently curetted post-surgical lesion, or a dental extraction performed without observing asepsis or antisepsis regulations, can trigger post-extractional alveolitis, soft-tissue suppression, abscesses, thrombophlebitis.

The importance of acute infections in diabetics is not only due to the severity of their development but also to the fact that they aggravate the pre-existing metabolic balance, causing a real "metabolic derailment" that can sometimes lead to acidotic coma within a few hours.

The pre-anesthetic and preoperative preparations in the Oral and Maxillofacial Surgery Clinic were modeled by the conditions in which diabetic patients were present: adult patients with diabetes without vascular complications, balanced with diet and oral antidiabetic medication, adult patients with diabetes who exhibits vascular lesions, but balanced with diet and oral anti-diabetic medication; patients with diabetes mellitus inadequate, young, diabetic patients with come, precome and past infections.

As a general rule we applied without exception to suppress endocrine-vegetative reactions, we administered oral premedication (Diazepam, Nitrazepam, Flunitrazepam) one hour prior to each dental surgery treatment in all four categories of patients diabetics.

The second rule was prophylaxis with oral or parenteral antibiotic therapy, started on the morning of intervention, with a minimum of 4 hours preoperatively. The type of antibiotic, the dose and the route of administration, we chose according to the severity of diabetes, in collaboration with the diabetologist.

And the third rule was to perform dental care proposed only under local quality regional anesthesia, with 1-2% non-adrenaline xylene, to reduce as much as possible glycogenolysis and glycemia on the one hand, and on the other hand predispose to increase adrenal cortical secretion.

Conclusions

Diabetes mellitus is the most common metabolic disease, for which the dentist, in the large number of patients presenting daily for dental care, is directly implemented into the moral and legal responsibility of these *fragile* patients.

Through the training of a dentist, he is not in a position to have the competence of a diagnosis of certainty in diabetic mellitus disease, but following his medical history and physical examination, he recommends some biochemical laboratory exams in the, complementary, paraclinical examination.

Dental practitioner has the obligation to guide suspected patients to clinics or diabetes services; complex modern research has now indicated that the well-balanced metabolic diabetic patient is no more exposed to complications than an undiabetic patient.

The importance of diabetic requisite in dental practice is not only determined by the high frequency of complications requiring surgery, but also by the fact that in these patients any aggression, even limited, can cause entry into a vicious circle where the local lesion aggravates the diabetic state, and this, in turn, worsens the local development of lesions.

References

1. HINGANU, M.V., STAN, C.I., TARANU, T., HINGANU, D., Rom J Morphol Embryol, 58, no. 3, 2017, p. 851.
2. BUCUR, A., VILA, N., LOWRY, J., ACERO, J., Compendiu de chirurgie oro-maxilofaciala, vol. 1 si 2, Editura Q Med Publishing, Bucuresti, 2009.
3. ADEYEMO W.L., LADEINDE A.L., Contemp. Dent. Pract, 17, no. 3, 2006, p. 40.
4. *** American Dental Association Council, 2003: Guidelines for teaching the Comprehensive Control of Pain and Anxiety in Dentistry . Chicago Amer. Dent. Association
5. ALDEA H., ALDEA I., 2001 : Aspecte psihologice ale relatiei pacient -medic stomatolog. Supl. Rev. Med. Stom., 5 (6): 245-247.
6. *** American Diabetes Association, 2000; Clinical Practice Recommendations, Committee Report: Report of the Expert Committee on the Diagnosis and Classification of Diabetes. Diabetes Care, 23(1):45-48 13.
7. *** American Diabetes Association, 2002: Standards of medical care for patients with diabetes. Diabetes Care, 25(1): S35-S49
8. HINGANU, D., EVA, I., STAN, C., HINGANU, M.V., Rom J Morphol Embryol, 57, no.1, 2016, p. 161.
9. *** American Heart Association, 2004 : Heart Disease and Stroke Statistics. Update, Dallas
10. *** American Society of Anesthesiologists , 2003: Manual for anesthesia department organization and management. A.S.A., Park Ridge, Ill
11. ANTHONY T., 2003: Practicing for life. The dentist's role in managing the diabetic patient. Global Health Nexus, 5(2): 35-1.
12. ANTHONY T., 2004: What the mouth has to say about diabetes. Careful examinations can avert serious complications. University of Minnesota Medical School/Minneapolis, U.S.A.
13. ARCURI, C., CECCHETTI, F., Minerva Stomat., 55, no1, 2006, p. 17-13.
14. ARTEAGOTIA I., DIEZ A., Oral Surg .Oral Med. Oral Pathol. Oral Radiol. Endod., 100, 2005, p.1
15. HINGANU, D., HINGANU, M.V., BULIMAR, V., ANDRONIC, D., Rev. Chim.(Bucharest), 69, no. 2, 2018, p. 371.
16. BUCUR, A., Compendiu de chirurgie oro-maxilo-faciala, Vol.1, Editura Q Med Publishing, Bucuresti 2009
17. VORONEANU, M., BUCUR, A., VICOL, C., DINESCU, N.N., 2007: Actualitati privind riscul urgentelor medicale in cabinetul de medicina dentara. Edit. Pim.

Manuscript received: 14.11.2017