

Tranexamic Acid - Major Antifibrinolytic Agent Used to Achieve Hemostasis in Hemophilic Patients with Anti-Factor VIII Anti-Bodies Who Must Undergo Total Joint Replacement

OANA VIOLA BADULESCU¹, MANUELA CIOCOIU^{1*}, NINA FILIP^{2*}, VLAD VERINGA³

¹Grigore T. Popa University of Medicine and Pharmacy, Faculty of Medicine, Department of Pathophysiology, Morfo-Functional Sciences (II), 16 Universitatii Str., 700115, Iasi, Romania

²Grigore T. Popa University of Medicine and Pharmacy, Faculty Of Medicine, Department of Biochemistry, Morpho-functional Sciences (II), 16 Universitatii Str., 700115, Iasi, Romania

³Grigore T. Popa University of Medicine and Pharmacy, Faculty of Medicine, Department of Orthopedics and Traumatology Surgical Sciences (II), 16 Universitatii Str., 700115, Iasi, Romania

Hemophilia is a congenital coagulopathy characterized by a deficiency of coagulation factor VIII or IX. The main complication of this hemopathy is represented by the hemorrhagic phenomena that affect mainly the musculoskeletal system. Of the various chronic complications of this condition, hemarthrosis is responsible for the onset of chronic arthropathy, which is a disabling condition. In addition to hematologist-prescribed coagulation factor replacement therapy, acute hemarthrosis and chronic arthropathy management requires close collaboration with both orthopedic surgeons and physiotherapists. This multidisciplinary collaboration is essential both to prevent the onset of hemarthroses and to manage acute bleeding episodes, to assess joint function and to effectively treat hemophilic chronic arthropathy. Hemophilic arthropathy causes significant joint instability and reduced mobility or even total ankylosis, which may lead to permanent disability and hence to a decrease in the patient's quality of life. From an orthopedic point of view, disabling hemophilic arthropathy may be treated by surgery. Achieving effective hemostasis is vital in order to be able to perform these extremely difficult surgical procedures, due to the high risk of bleeding. This paper aims at highlighting the hemostatic efficacy of tranexamic acid in orthopedic surgery in hemophilic patients who must undergo total joint replacement.

Keywords: hemophilia, arthropathy, hemarthrosis, tranexamic acid

Hemophilia is a congenital hemorrhagic condition (gonosomal recessive, connected to chromosome X) characterized by thromboplastin formation deficiency due to coagulation factor VIII (hemophilia A) or factor IX (hemophilia B) deficit.

Unlike primary hemostasis disorders such as thrombopathies, thrombocytopenia, or von Willebrand factor (VWF) deficiency, characterized by skin and mucosa bleeding, hemophilic patients experience deep bleeding that primarily affects the muscles and large joints. In severe hemophilia, 90% of the bleeding episodes involve the musculoskeletal system, and in 80% of the cases the joints are involved [1]. Bleeding mainly takes the form of hemarthroses, which often occur spontaneously, without specified etiology, and have repetitive character. In patients with severe hemophilia, initial hemarthrosis occurs when the locomotor system is used for the first time, i.e. when the baby starts to walk. In the absence of replacement therapy, patients with severe hemophilia may suffer more than 30 hemarthroses per year. The frequency of bleeding and its location tend to vary with the age of the patient. While the knees and elbows are most often affected in patients over the age of 30, adolescents and young adults usually experience bleedings that affect the ankles despite adequate replacement therapy [2].

Based on clinical manifestations, three stages of hemarthrosis may be distinguished: acute hemarthrosis that is treated by coagulation factor replacement therapy and rehabilitation, usually without clinically detectable

sequelae; sub-acute hemarthrosis occurs after repeated episodes of bleeding in the same joint - at this stage, the joint and surrounding soft tissues are not fully recovered, whereas clinical signs of joint injury persist and are detectable between bleeding episodes; chronic arthropathy develops after repeated bleeding episodes in the joints, resulting in a significant loss of muscle function and muscle-tendon contractures.

Recurrent hemarthrosis episodes generate a proliferative and destructive chronic synovitis, progressive destruction of joints and consecutive hemophilic arthropathy. Initially, chronic knee arthropathy is characterized by joint hypertrophy due to chronic synovitis, in contrast to quadriceps atrophy. There follows an irregular epiphyseal hypertrophy that deforms the joint and limits the range of motion (ROM), with a tendency to contracture when the leg is flexed. In severe forms, static changes such as the genu valgum, lateral and posterior tibial subluxation, and rotational deformities leading to severe disabilities may occur. Chronic ankle arthropathy affects mainly the tibiotalar and/or subtalar joint. Movement becomes painful and stiffness of joints is noticed, especially when the patient gets out of bed in the morning. The movements of the patient in dorsiflexion and plantar flexion, as well as the inversion and eversion movements become limited. [3] Vicious positions like deformation of the equine pelvis or plano-valgus tend to set in. Chronic elbow arthropathy sets in insidiously, resulting in loss of flexion-extension and pronosupination, joint instability and sometimes neurological complications such as impaired

* email: mciocoiu2003@yahoo.com; zamosteanu_nina@yahoo.com

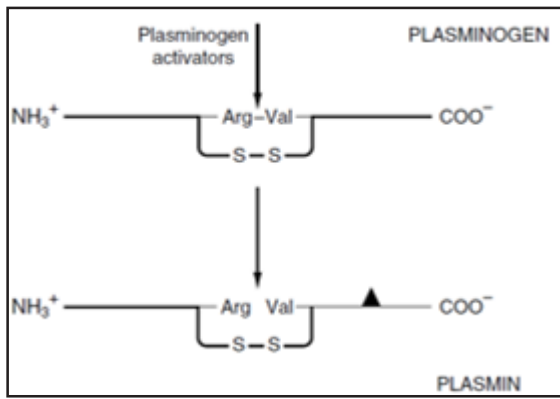


Fig. 1. Activation of plasminogen

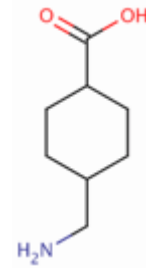


Fig. 2. Chemical structure of tranexamic acid

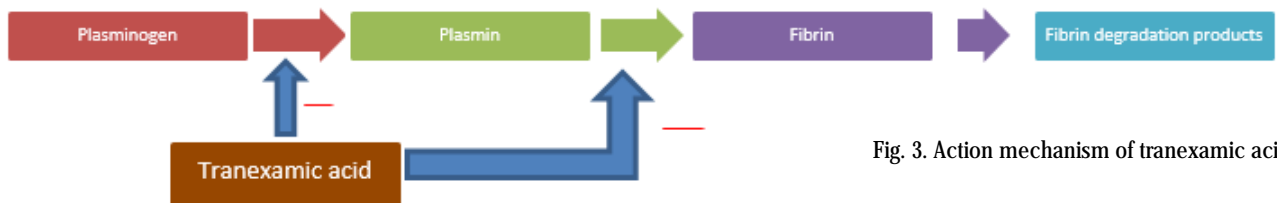


Fig. 3. Action mechanism of tranexamic acid

ulnar nerve (impingement) caused by osteophytes. In more advanced stages, a narrowing of the epiphysis surfaces may be noticed with the loss of joint congruence, and with the instability and degradation of the remaining joint surfaces. Advanced bone changes such as flattening of the femoral condyles or aseptic necrosis of the talar dome, as well as the presence of subchondral cysts and geodes are characteristic features of hemophilic arthropathy.

From the orthopedic point of view, total joint replacement is recommended in the following cases: joint pain and disability, which do not respond to conservative therapy, as well as advanced radiological changes. The objectives of this procedure are to reduce pain, improve joint amplitude and correct deformation.

From a hematological standpoint, postoperative bleeding is the major complication that may occur in hemophilic patients who underwent joint replacement surgery. Considering this life-threatening complication, most joint replacement surgeries in hemophilic patients are scheduled beforehand, in order to ensure the required amount of coagulation factor for the substitution therapy. Hemostatic adjuvant medication such as tranexamic acid, as anti-fibrinolytic agent, may play an essential role in the management of hemophilia patient hemostasis with inhibitors present.

Tranexamic acid was initially used about 40 years ago in cardio-thoracic surgery, in gynecological hemorrhage control, as well as in the control of hemorrhages following major traumas. Also, the effectiveness of tranexamic acid has also been studied in hematological pathologies such as von Willebrand factor deficiency, hemophilia or thrombocytopenia [4]. It is frequently and successfully used in orthopedic surgery to reduce perioperative hemorrhagic phenomena, especially in patients with total hip or knee replacement.

Tranexamic Acid

The coagulation system is normally in a state of dynamic equilibrium in which fibrin clots are constantly being laid down and dissolved. This process is termed fibrinolysis. Plasmin, the serine protease mainly responsible for degrading fibrin and fibrinogen, circulates in the form of its inactive zymogen, plasminogen, and any small amounts of plasmin that are formed in the fluid phase under physiologic conditions are rapidly inactivated by the fast-acting plasmin inhibitor, α_2 -antiplasmin. Plasminogen binds to fibrin and thus becomes incorporated in clots as

they are produced; since plasmin that is formed when bound to fibrin is protected from α_2 -antiplasmin, it remains active. Activators of plasminogen of various types are found in most body tissues, and all cleave the same Arg-Val bond in plasminogen to produce the two chain serine protease, plasmin (fig. 1) [5].

Tranexamic acid, a synthetic derivative of the amino acid lysine, is an anti-fibrinolytic drug that competitively inhibits plasminogen activation in plasmin.

Figure 2 shows the chemical structure of tranexamic acid (1-(aminomethyl) cyclohexane-4-carboxylic acid) (4-(aminomethyl) cyclohexane-1-carboxylic acid).

Plasmin is formed by proteolytic activation of plasminogen, an inactive precursor that has high affinity for fibrin clots.

The action mechanism of tranexamic acid (fig. 3) is explained by its binding to the lysine residues found in plasminogen binding sites, thus blocking plasminogen activation and fibrinolytic activity of plasmin, which is no longer formed.

Given its increased affinity for plasminogen binding sites, tranexamic acid competitively inhibits the activation of plasminogen and, at high concentrations, it uncompetitively inhibits plasmines, resulting in inhibition of fibrinolysis.

Experimental part

Material and method

A multidisciplinary team (hematologist-orthopedist-intensive care specialist) carried out the orthopedic examination of two patients with severe hemophilia A (factor VIII <1%) with inhibitors present, with chronic hemophilic arthropathy accompanied by pain and functional impairment and with severe motor deficit, who needed joint replacement. Therefore, they underwent total left hip replacement surgery and total left knee replacement surgery, respectively. The orthopedic surgery benefited from hematological support according to well-established specialized protocols (Giangrande protocol), which provided the necessary amount of coagulation factor for substitution therapy. Concurrently, tranexamic acid 25 mg/kg body weight was administered intravenously at 6-8 h intervals according to the abovementioned protocol. The hemoglobin and hematocrit levels, parameters of the coagulation profile, transfusion requirements, and possible orthopedic complications were monitored both during and after the surgery. Hemostasis was perfect and the postoperative bleeding evolution was also very good; from

the paraclinical point of view, the hemoglobin level decrease that was detected did not require blood transfusion. Postoperative bleeding was minimal in both cases, of about 400 mL, similar to any regular patient not suffering from hemophilia. Since the coagulation profile normalized after the substitution therapy, anticoagulation treatment consisting of low molecular weight heparin (Enoxaparin) was given to prevent thromboembolic complications, which could have prolonged the duration of hospitalization. From the orthopedic point of view, the patients' postoperative evolution was positive in both cases, with significant reduction in hip and knee joint pain, with improvement in joint function and implicitly with increased quality of life.

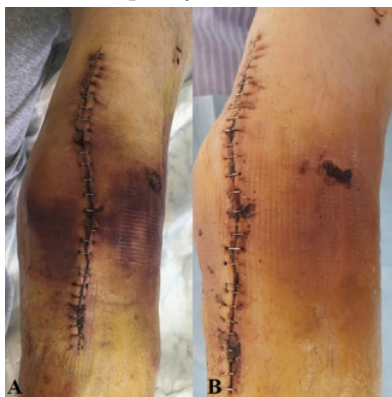

Fig. 4. A-B Postoperative wound healing process.
A - Postoperative wound at 7 days.
B - Postoperative wound at 12 days

Results and discussions

As concerns its clinical use, tranexamic acid should be administered early, within the 3 h preceding and following the surgery, in order to efficiently inhibit fibrinolysis before the occurrence of major coagulopathy induced by hemorrhage or by other related mechanisms [6]. The tranexamic acid has anti-inflammatory properties such as: reduces some of the inflammatory response markers - IL-6, CK, generated by fibrin [7]. The anti-inflammatory effect associated with the platelet effect may partially explain, along with the diminution of bleeding, the rate of occurrence of myocardial infarction [8].

Tranexamic acid has a short half-life of 3 h, does not undergo biotransformation and, unlike aprotinin, does not cause allergies. The therapeutic window may be wide, as there are no overdose effects described in literature, except for convulsions at very high doses, suggesting that epilepsy may be a contraindication. This explains the lack of consensus on the doses used in orthopedics. Clinical trials have shown that a 80% reduction in fibrinolysis activity was sufficient to meet clinical needs, obtained at a 10 mg/L tranexamic acid concentration [9]. Though its hepatic metabolism is minimal, caution is applied when it is used concomitantly with prothrombotic medication (contraceptive medication, coagulation factor concentrates) [10] Tranexamic acid penetrates the hemato-encephalic and ocular barrier, its cerebrospinal concentration being approximately 10% of the plasma concentration. It is diffused in a similar manner in the synovial membranes and joint fluid.

Orthopedic clinical trials [11-13] claim that there is no clinical evidence of increased thromboembolic risk, myocardial infarction, stroke, deep venous thrombosis or pulmonary embolism associated with tranexamic acid use. Some cases of cerebral ischemic events associated with the presence of the heterozygous phenotype MTHFR C677T (methylene tetrafolate transferase) have been reported in young people [14].

Calapai G. et al. (wide review -2015) described the main adverse reactions found in 28 studies, in which various

doses of tranexamic acid were used in cardiac, orthopedic and gynecological surgery: skin sensitization (6 cases), cerebral infarction 6 cases), myocardial infarction (5 cases) and pulmonary embolism (4 cases), these being the most frequent. They also detected: convulsive phenomena (3 cases), acute renal cortical necrosis (2), ligneous conjunctivitis (2).

In a wide-spreading meta-analysis, Kagoma et al. [15] support the use of tranexamic acid in orthopedics, as it reduces blood loss and transfusion risk without increasing the thromboembolic risk, the tranexamic acid dose being used being 10-15 mg/kg. In a broad retrospective analysis, Poeran et al. [16] study tranexamic acid efficiency in total joint replacement surgery: it decreases transfusion rate (7.7 vs. 20%), it decreases the efficiency of thromboembolic events (0.6% vs. 08%) and it decreases the incidence of acute renal impairment (1.6 vs. 1.8%). They also noted a decrease in the overall complications, mechanical ventilation and admission to the intensive care ward rates. Moreover, a significant reduction in hospitalization costs was noted for patients who were administered tranexamic acid. With higher doses (1g, 2g, 3g), the transfusion needs decrease, while the risk of complications remains the same. This study was conducted on a group of 872,416 patients in 510 hospitals in the United States.

In total joint replacement surgery, tranexamic acid is administered intravenously in most cases.

Hippala et al. (1997) showed that intravenous tranexamic acid administration is beneficial, having no higher risk of thromboembolic events. In a meta-analysis carried out in 2016 [17], Moskal et al. confirm this, by investigating the effect of intravenous tranexamic acid administration in total joint replacement surgery: there is a reduction of approximately 50% of the transfusion rate as compared to the placebo group. Lozanos' meta-analysis (9 randomized trials) shows that iv use of tranexamic acid in total joint replacement surgery leads to a significant reduction in perioperative bleeding, yet it does not assess possible thromboembolic complications. After intravenous administration, the tranexamic acid penetrates into the membranes and synovial fluid, reaching concentrations similar to plasma concentrations after 15 min [18].

Regarding the tranexamic acid administration method, its combined (intravenous and topical) administration has been shown to be effective by Yuan et al. in a meta-analysis carried out in 2016 on patients who underwent total knee replacement surgery [19]. The superiority of combined tranexamic acid administration in cases of total joint replacement surgery was also demonstrated by Xie et al. in a study published in 2016 [20] and supported by Wu et al [21] in a study on the use of tranexamic acid in prosthesis revision.

Regarding the optimal dose of tranexamic acid that should be administered in total joint replacement, a recent meta-analysis (46 randomized trials) on no less than 2925 patients undergoing orthopedic surgery, doses of $< / >$ 15 mg/kg, administered in single/repeated bolus, were compared. Tranexamic acid administration was associated with a mean total blood loss decrease of -408 mL. The transfusion needs decrease appears to be the same - single/repeated bolus, and the percentage of deep venous thrombosis was similar regardless of dose/placebo.

The two cases of joint replacement surgery carried out in our Orthopedics Clinic confirmed the findings of the studies referred to above; in our hemophilic patients who underwent total knee and hip replacement surgery, the use of tranexamic acid in combination with coagulation factor replacement therapy led to a comparative bleeding

with non-hemophilic patients who did not need blood transfusion; also there occurred no thrombo-embolic phenomena.

Conclusions

The decrease in transfusion needs in major orthopedic surgery procedures due to the use of tranexamic acid is supported by numerous clinical trials. Tranexamic acid does not increase or diminish the thromboembolic risk associated with this type of surgery. Absolute contraindications are a history of seizures and severe renal failure. Although the optimal dose of tranexamic acid is not well-defined, there is clearly a *dose-related effect* in orthopedic surgery.

In orthopedic surgery of hemophilic patients, tranexamic acid used as anti-fibrinolytic agent has been proven to be efficient in reducing hemorrhagic phenomena and blood transfusion needs of patients undergoing total hip or knee replacement surgery. This was also confirmed in the two cases of total joint replacement surgery conducted in our hospital.

References

1. SIRBU, P.D., TUDOR, R., BEREA, G., SCRIPCARU, A., CIUBARA, B., BADULESCU, O.V., Bipolar Polyethylene Radial Head Arthroplasty in Posttraumatic Unstable Elbows Prosthetic design and clinical results, *Mat. Plast.*, **54**, no. 2, 2017, p. 298-301
2. SIRBU PD, MIHAILA RI, GHIONOIU G, BRUJA R, ASAFTEIR, Minimally invasive plate osteosynthesis (MIPO) in proximal and distal fractures of the tibia, Conference: 7th European Trauma Congress Location: Ljubljana, SLOVENIA Date: MAY 14-17, 2006; PROCEEDINGS OF THE 7TH EUROPEAN TRAUMA CONGRESS, Pages: 349-+ , Published: 2006
3. SIRBU PD, CARATA E, PETREUS T, ASAFTEI R, BOTEZ P, Minimally Invasive Plate Osteosynthesis with Systems with Angular Stability in Complex Distal Femoral Fractures. Design, Biomechanics and Clinical Results, Conference: ECSIS Symposium on Advanced Technologies for Enhanced Quality of Life (AT-EQUAL 2009) Location: Tech Univ, Iasi, ROMANIA Date: JUL 22-26, 2009, Sponsor(s): European Ctr Secure Informat & Syst; Univ Edinburgh; Univ Med & Pharmacy; Romanian Acad; Inst Comp Sci; Soc Adapt & Evolvable Hardware & Syst AT-EQUAL 2009: 2009 ECSIS SYMPOSIUM ON ADVANCED TECHNOLOGIES FOR ENHANCED QUALITY OF LIFE: LAB-RS AND ARTIPED, 2009, Pages: 36-+, Published: 2009
4. SIRBU PD, PETREUS T, MUNTEANU FL, PERTEA M, LUNCA S, POROCH V, BOTEZ P, Clinical Experience with a Macroporous Synthetic Bone Substitute (Eurocer) in the Treatment of the Patients with Bone Defects International Conference on Advancements of Medicine and Health Care through Technology IFMBE Proceedings, 2011, Volume 36. Part 5, 358-368, DOI: 10.1007/978-3-642-22586-4_75
5. RODWELL V, BENDER D, BOTHAM KM, KENNELLY PJ, WEIL PA. Harpers illustrated biochemistry 30th edition. McGraw Hill Professional Google Scholar; 2015 Mar 22.
6. BLUMBERG N, KIRKLEY SA, HEAL JM. A cost analysis of autologous and allogeneic transfusion in hip-replacement surgery. *Am J Surg.*
7. BLANIE A, BELLAMY L, RHAYEM YC, et al. Duration of Postoperative Fibrinolysis after Total Hip or Knee Replacement: A Laboratory Follow-up Study. *Thrombosis Research* 2013;131:6-11E.
8. IRISSON AF, KERBAUL ABS, PARRATE CY, HEMON AJ-N, ARGENSON CN, ROSENCHER DL, BELLAMY L. Cinétique du saignement en chirurgie orthopedique majeure: implications pour la prise en charge perioperatoire. *Annales françaises d'anesthesie et de reanimation*. Volume 32, n° 3, pages 170-174 (mars 2013)
9. KLENERMAN L, CHAKRABARTI R, MACKIE I: Changes in haemostatic system after application of a tourniquet. *Lancet* 1977; 970-972
10. CRASH C, ROBERTS I, SHAKUR H, et al. The importance of early treatment with tranexamic acid in bleeding trauma patients: an exploratory analysis of the CRASH-2 randomised controlled trial. *Lancet* 2011;377:1096-1101
11. JIMENEZ JJ, IRIBARREN JL, LORENTE L et al.: Tranexamic acid attenuates inflammatory response in cardiopulmonary bypass surgery through blockade of fibrinolysis: a case control study followed by a randomized double-blind controlled trial. *Crit Care* 2007; 11: R117.
12. CRASH-2 collaborators. Effects of tranexamic acid on death, vascular occlusive events, and blood transfusion in trauma patients with significant haemorrhage (CRASH-2): a randomised, placebo controlled trial. *Lancet* 2010;376:23-32
13. FERRING PHARMACEUTICALS. LYSTEDA TM (tranexamic acid) Tablets - PI [Internet]. Parsippany: Ferring Pharmaceuticals; 2013 [cited 2014 Dec 7]. p. 1-20.
14. JERATH A, WASOWICZ M, YANG Q, PANG KS: Safer tranexamic acid dosing for patients with renal dysfunction undergoing cardiac surgery [Internet]. *ASA Abstract*. ASA; 2013
15. DUNN CJ, GOA KL (1999) Tranexamic acid: a review of its use in surgery and other indications. *Drugs* 57: 1005-1032
16. KAGOMA YK, CROWTHER MA, DOUKETIS J, BHANDARI M, EEIKELBOOM J, LIM W: Use of antifibrinolytic therapy to reduce transfusion in patients undergoing orthopedic surgery: a systematic review of randomized trials. *Thromb Res. Elsevier B.V.* 2009; 123: 687-696.
17. SUKEIK M, ALSHRYDA S, HADDAD FS, MASON JM: Systematic review and meta-analysis of the use of tranexamic acid in total hip replacement. *J Bone Joint Surg Br* 2011; 93: 39-46.
18. ALSHRYDA S, SARDA P, SUKEIK M, NARGOL A, BLENKINSOPP J, MASON JM: Tranexamic acid in total knee replacement: a systematic review and meta-analysis. *J Bone Joint Surg Br* 2011; 93 1577-1585.
19. NARDIK, PELONE G, BARTOLO M et al.: Ischaemic stroke following tranexamic acid in young patients carrying heterozygosity of MTHFR C677T. *Ann Clin Biochem* 2011; 48: 575-578.
20. POERAN J, RASUL R, SUZUKI S et al.: Tranexamic acid use and postoperative outcomes in patients undergoing total hip or knee arthroplasty in the United States: retrospective analysis of effectiveness and safety. *BMJ* 2014; 349.
21. MOSKAL JT, CAPPS SG. Meta-analysis of Intravenous Tranexamic Acid in Primary Total Hip Arthroplasty. *Orthopedics* 2016;39:e883-92. 10.3928/01477447-20160526-02

Manuscript received: 23.08.2018